



Gestational trophoblastic neoplasia with cerebral and hepatic metastasis: a case report

Dr Nguyen Van Thang -NHOG






Introduction

- GTN is a malignant disease, mostly arises after molar pregnancy
- The rate of molar 1/650 pregnancy, 15-20% becomes GTN after molar
- The NHOG treats 300 GTN and 500 molar each year



Introduction

- GTN with metastasis 15%
 - Sites of metastasis: lung, vagina, brain, liver
 - Dangerous sites of metastasis, easily bleeding: brain, liver
- 




FIGO risk score

| Risk factor | Score | | | |
|---------------------|------------------|-----------------------------------|-----------------------------------|------------------|
| | 0 | 1 | 2 | 4 |
| Age | <40 | >40 | | |
| Antecedant P | mole | abortion | Term P | |
| Intrval P-chemo | <4 | 4-7 | 7-13 | >13 |
| hCG | <10 ³ | 10 ³ - 10 ⁴ | 10 ⁴ - 10 ⁵ | >10 ⁵ |
| Largest tumour size | | 3-5 | >5 | |
| Site metastasis | Lung | Spleen, kidney | gastro | Brain, liver |
| Number metastasis | | 1-4 | 5-8 | >8 |
| Pre chemo | | | mono | combine |



Background

- Low risk group <7 points: mono chemotherapy MTX/FA
 - High risk group ≥ 7 points: combined chemotherapy: EMACO, EMAEP, BEP, TP/TE
- 



Case report

- Female patient, 36 y-o, in Hanoi
- Antecedant pregnancy: 3 term-deliveries, last pregnancy 8 months (term delivery)
- History : menometrorrhagia after delivery, misdiagnosis of ectopic pregnancy, in endoscopy hepatic metastasis found ->NHOG



Case report

- Neuro signs: vomiting, headache, temporary blind
- Local signs: enlarged uterus, no vaginal metastasis, no ovarian cyst-theca lutein cysts
- β hCG: 32783 UI/l
- Chest Xray: metastasis
- Cerebral MRI: metastasis




Case report

- Abdo MRI: metastasis in liver
- hCG dosage cerebrospinal fluid

| 1 | 2 | 3 | 4 |
|----|-----|-----|----|
| 65 | 3,4 | 0,7 | <1 |



Case report

- Diagnosis: GTN high risk, FIGO 15 points
 - Treatment: multi-paradigm
 - Chemotherapy: EMACO
 - Surgery: hysterectomy, liver
 - Symptom: manitol 10%
 - Radiotherapy: if necessary
- 



Case report

- EMACO:

Etoposide 100mg/m²

MTX 100 mg/m² bolus, 200mg/m² IV

ActinomycinD 0,5mg

Cyclophosphamide 200mg/m²

Oncovine 1mg/m²




Case report

- Symptom : manitol 10%
- MTX intrathecal 12,5mg



Case report

- Day 3: hemorrhage peritoneal due to rupture hepatic metastasis
 - Laparotomy : hysterectomy and
 - Chemotherapy, manitol, MTX spinal
- 




Case report

- Neuro signes: improved
- hCG declined

| 21/2/2018 | 2/3/2018 | 15/3/2018 | 29/3/2018 | 12/4/2018 | 23/4/2018 |
|-----------|----------|-----------|-----------|-----------|-----------|
| 33738 | 10438 | 601 | 50 | 6 | 1,8 |



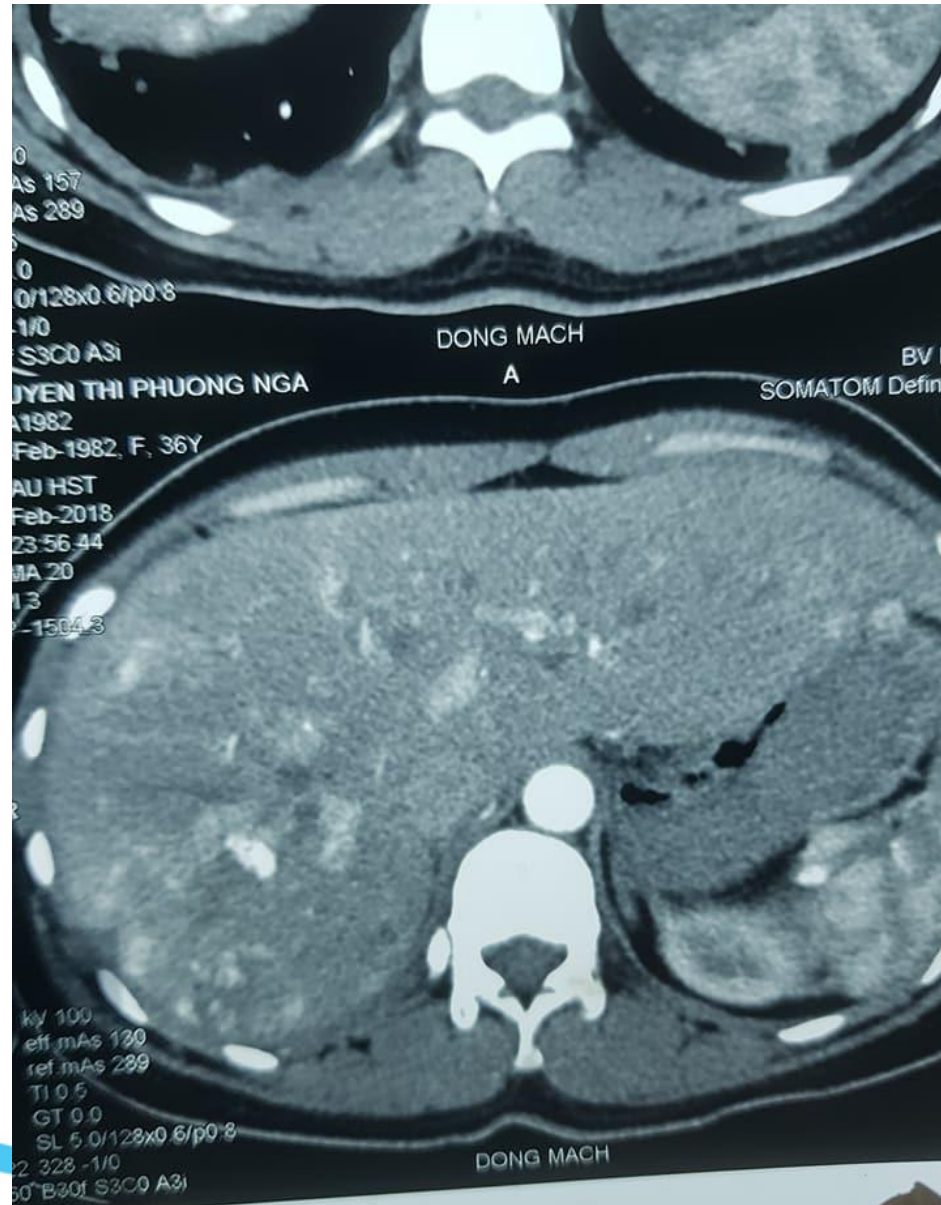
Discussion

- Diagnosis of GTN: menometrorrhagia, high dosage of β hCG postpartum
 - Diagnosis of metastatic site: MRI, chest Xray, spinal fluids, biopsy
 - Treatment: multi-paradigm
 - Laparotomy: longitudinal-medial
 - MTX intra thecal
- 



BỆNH VIỆN PHỤ SẢN TRUNG ƯƠNG

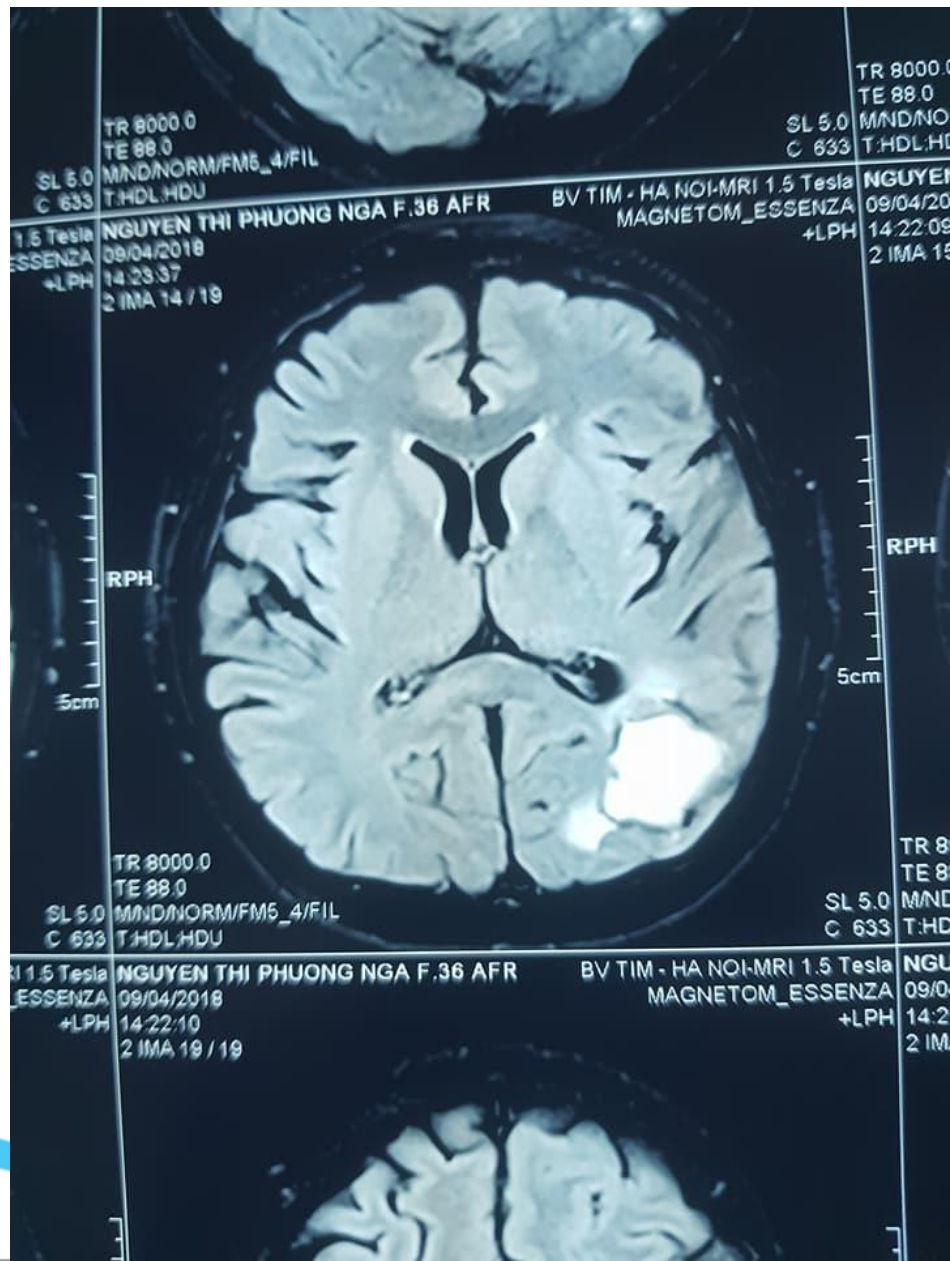
National Hospital of Obstetrics and Gynecology





BỆNH VIỆN PHỤ SẢN TRUNG ƯƠNG

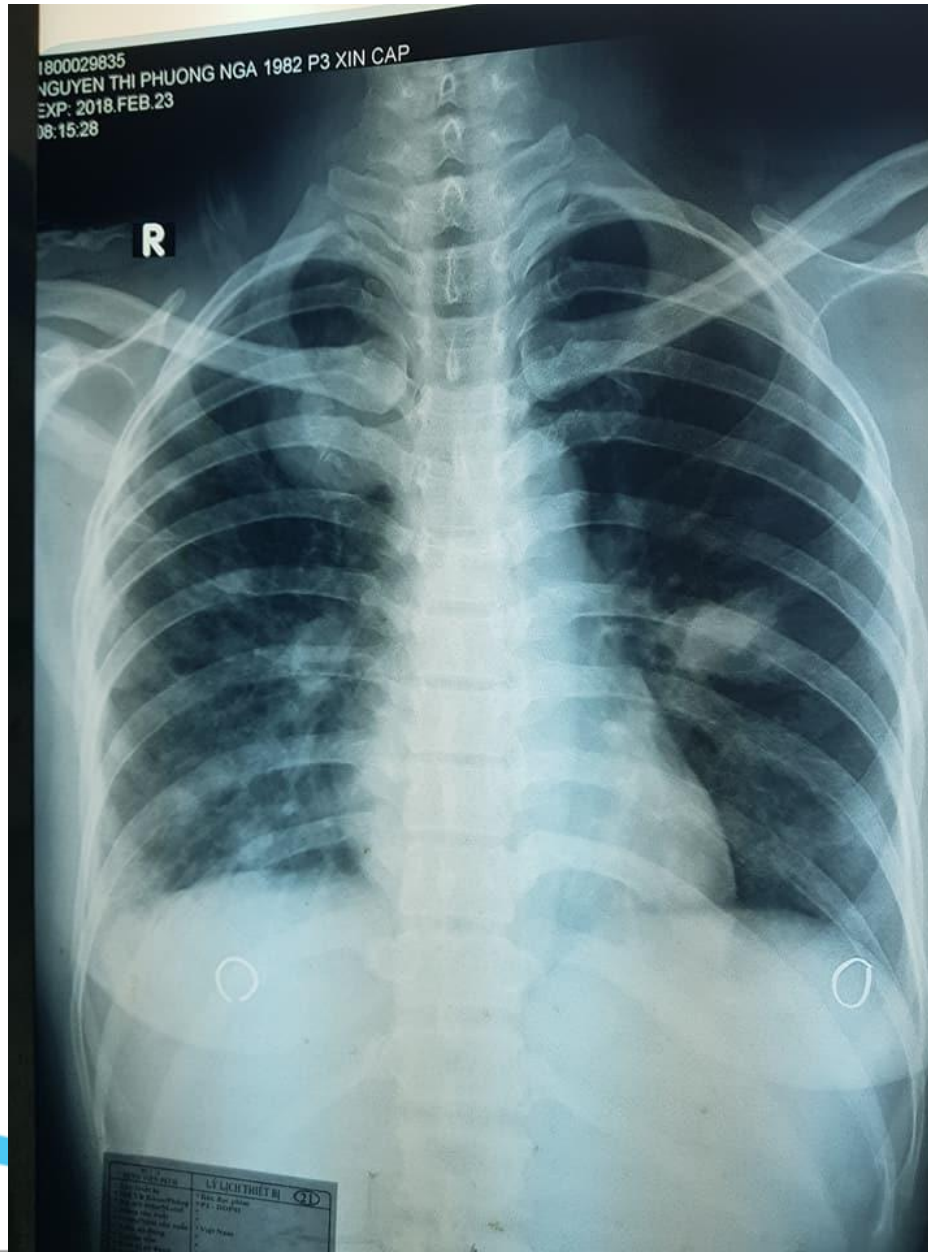
National Hospital of Obstetrics and Gynecology





BỆNH VIỆN PHỤ SẢN TRUNG ƯƠNG

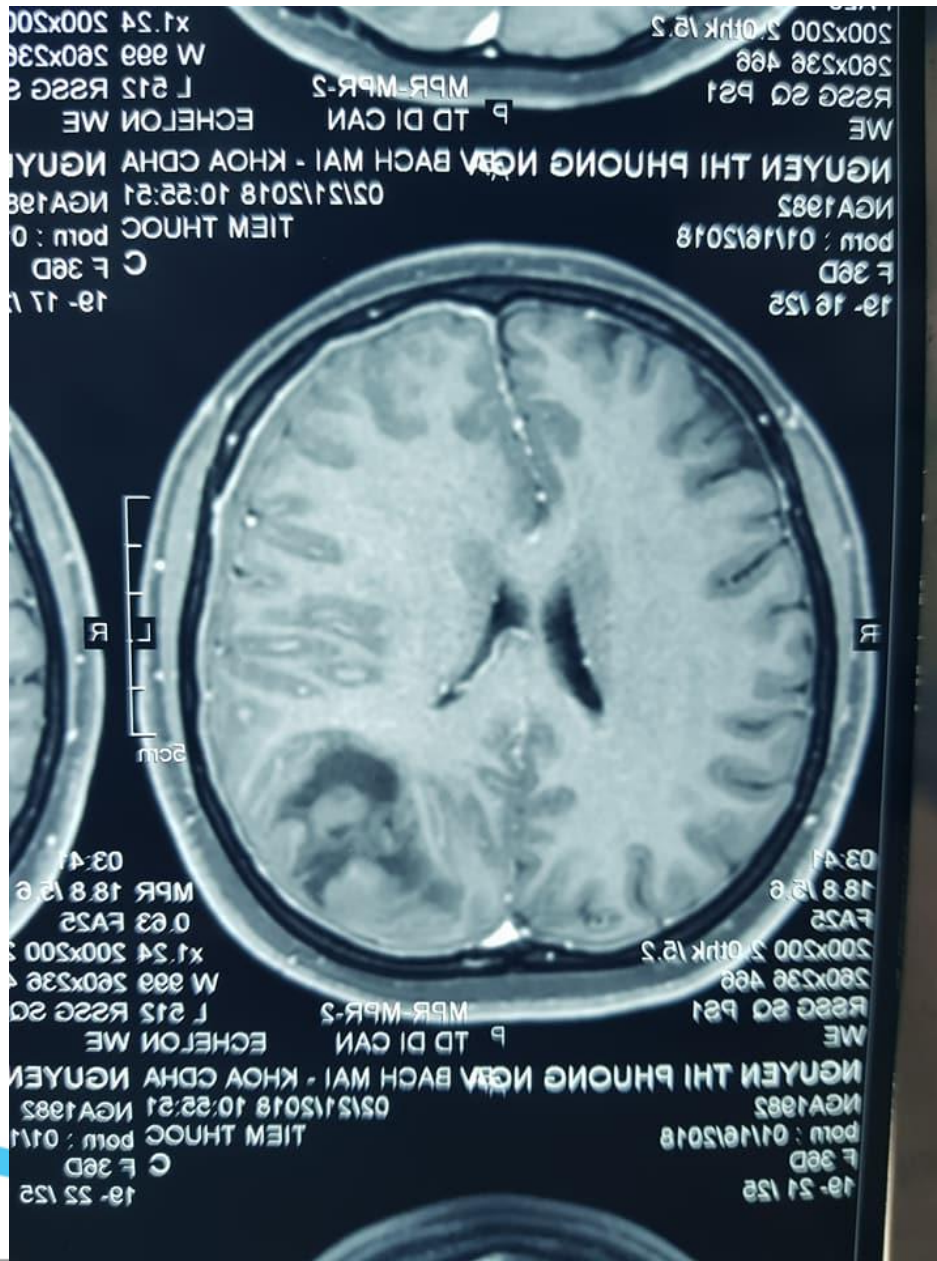
National Hospital of Obstetrics and Gynecology





BỆNH VIỆN PHỤ SẢN TRUNG ƯƠNG

National Hospital of Obstetrics and Gynecology





BỆNH VIỆN PHỤ SẢN TRUNG ƯƠNG

National Hospital of Obstetrics and Gynecology

Thank you for attention!

